



ACLS PRETEST SELF-ASSESSMENT

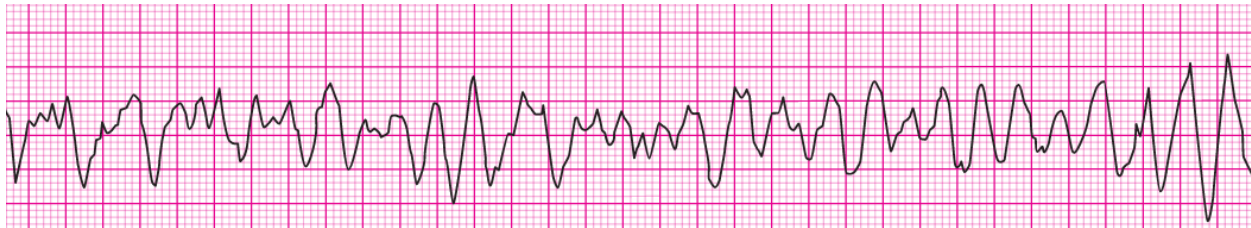
2015 American Heart Association Guidelines

Section 1: RHYTHM IDENTIFICATION

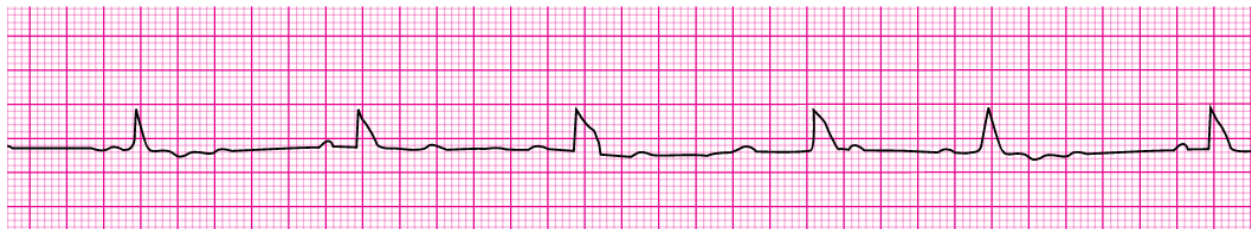Please use the box below to identify the following 20 rhythm strips:

Agonal rhythm / asystole	Atrial fibrillation	Atrial flutter	Ventricular fibrillation	Monomorphic ventricular tachycardia
Normal sinus rhythm	Polymorphic ventricular tachycardia	Pulseless electrical activity	Supraventricular tachycardia	Second-degree atrioventricular block (Mobitz II block)
Sinus bradycardia	Sinus tachycardia	Third degree atrioventricular block	Second-degree atrioventricular block (Mobitz I Wenckebach)	

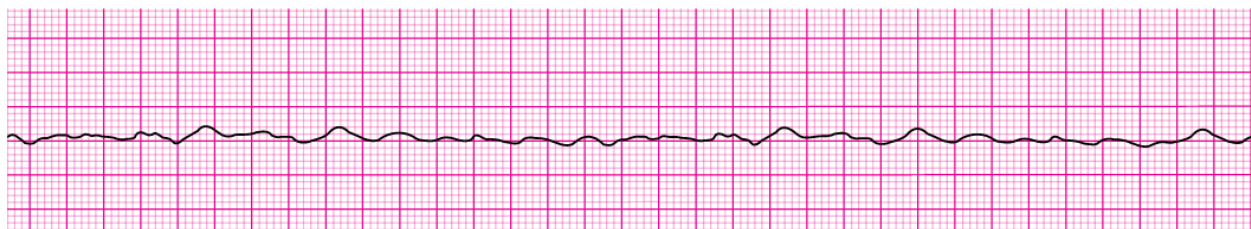
1. _____



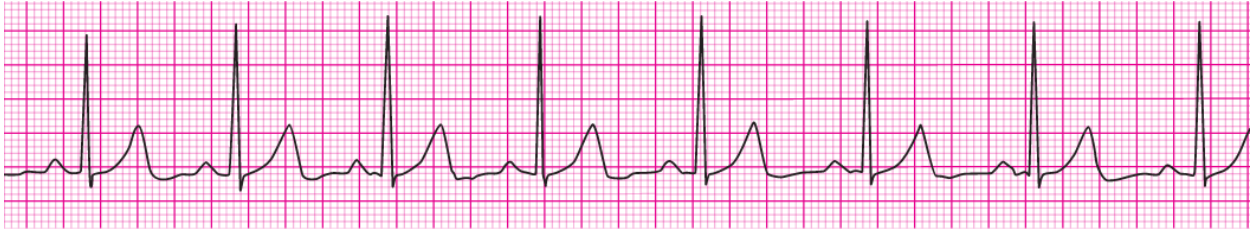2. _____



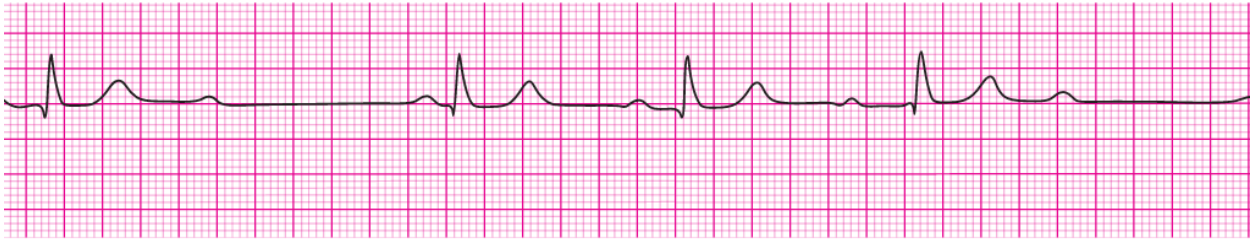
3. _____



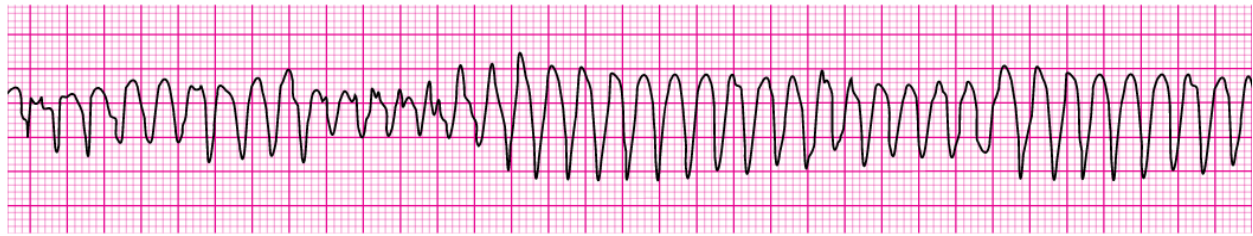
4.



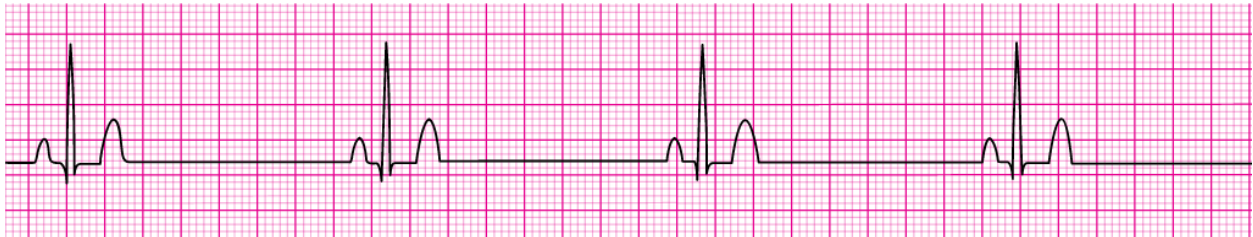5.



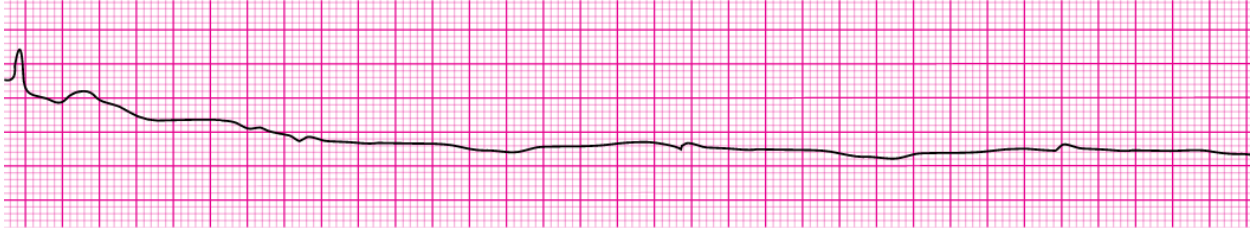6.



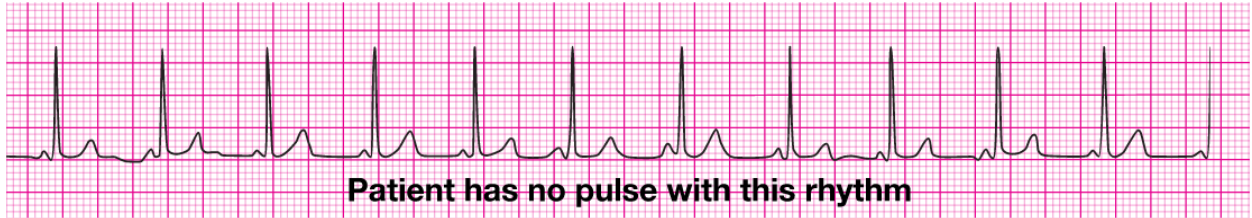
7.



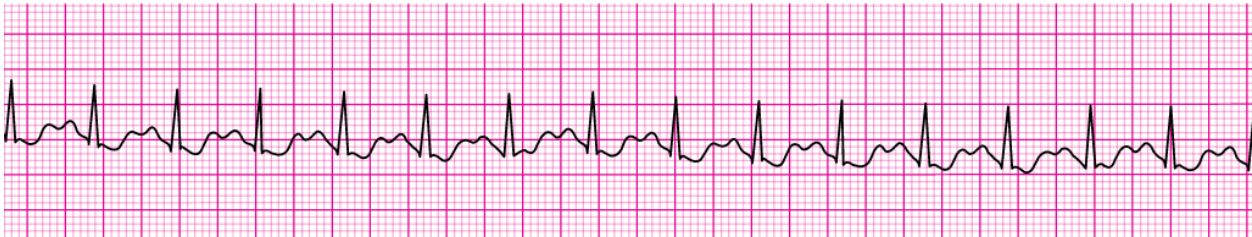8.



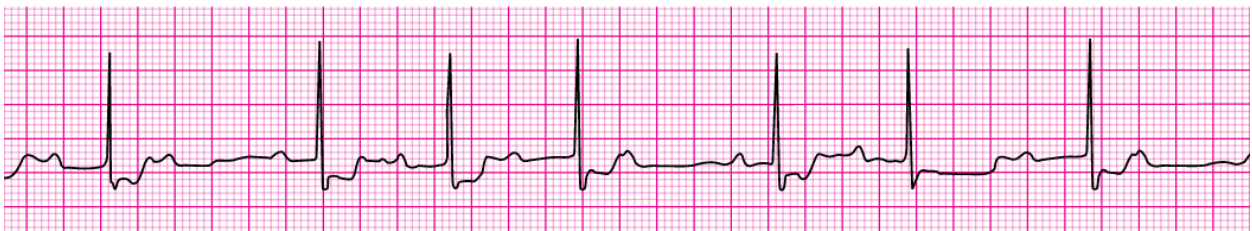9.



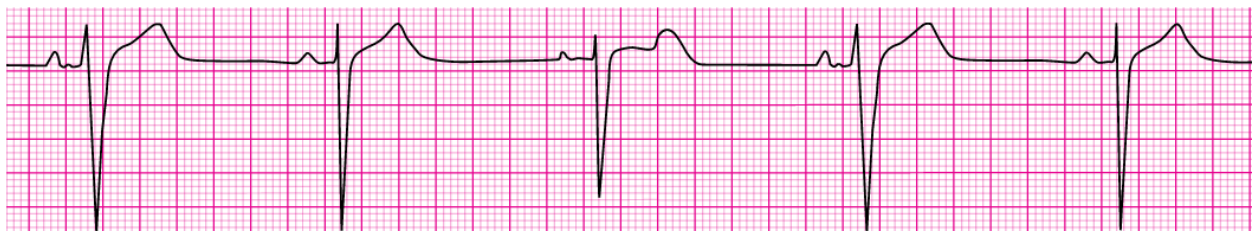
10.



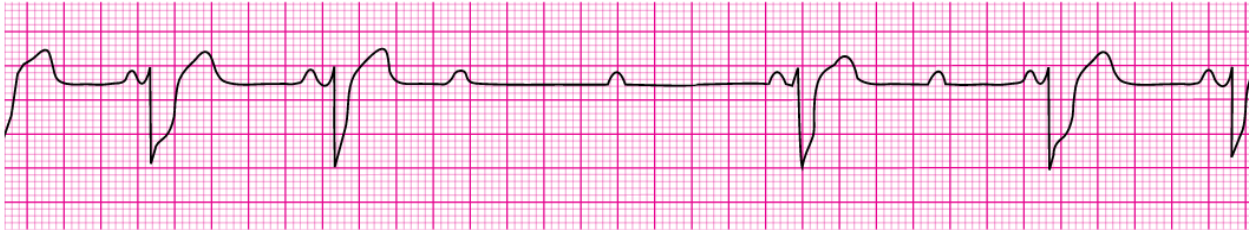11.



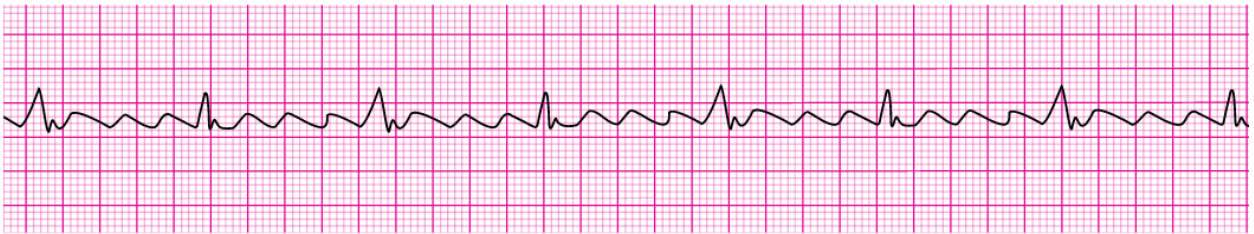
12.



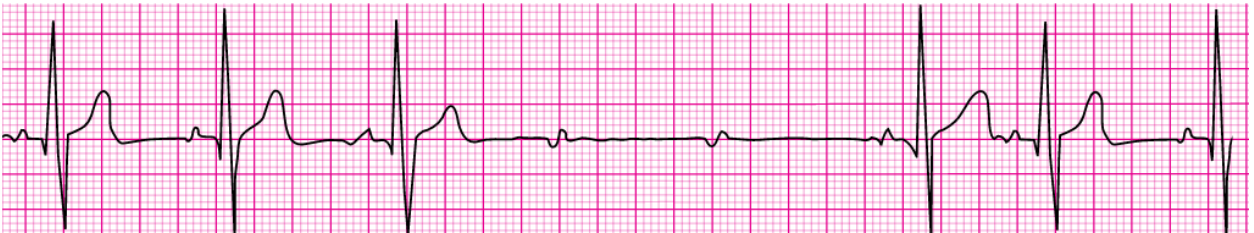
13. _____



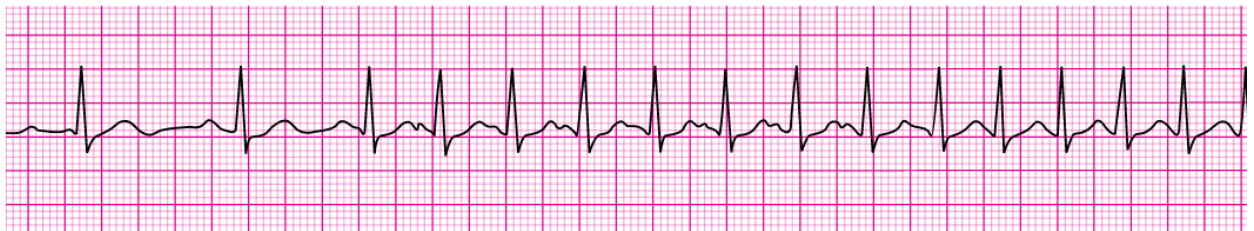14. _____



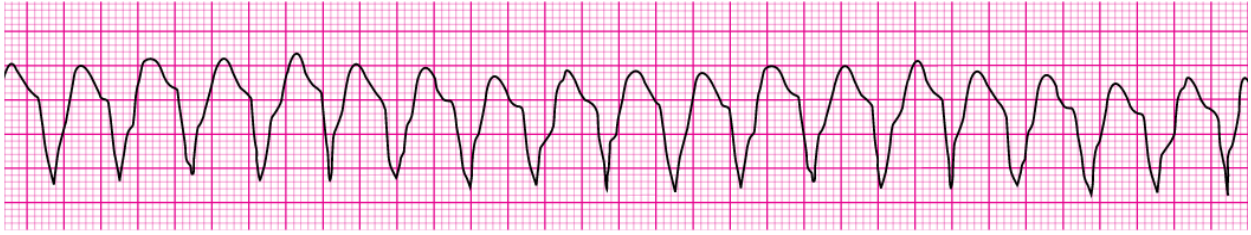15. _____



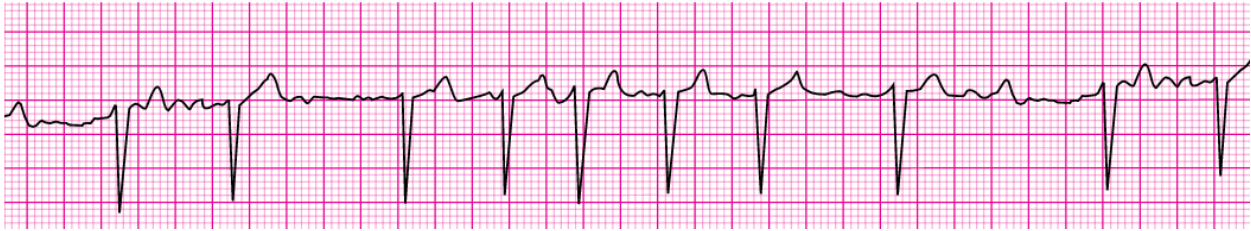
16. _____



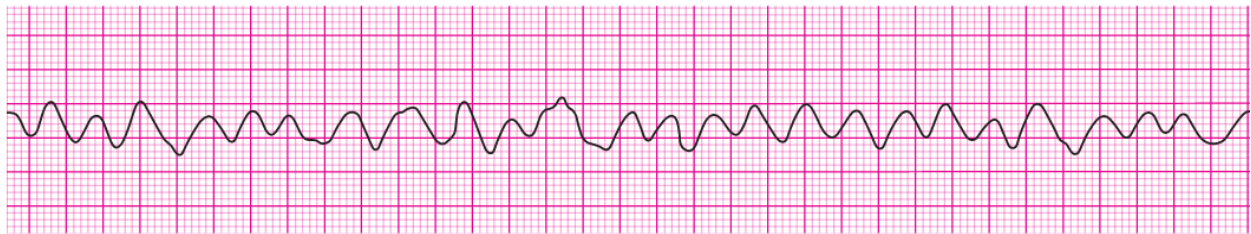
17. _____



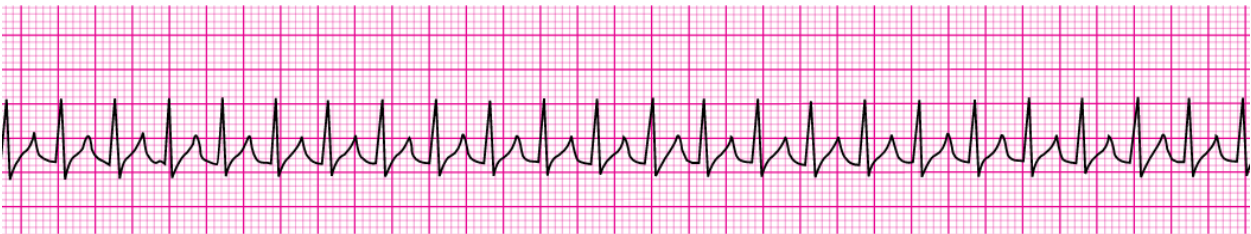
18. _____



19. _____



20. _____



Section 2: Pharmacology

- 1. A patient with STEMI has ongoing chest discomfort. Heparin 4000 units IV bolus and a heparin infusion of 1000 units per hour are being administered. The patient did not take aspirin because he has a history of gastritis, which was treated 5 years ago. What is your next action?**
 - a. Give aspirin 160 to 325 mg to chew
 - b. Give clopidogrel 300 mg orally
 - c. Give enteric-coated aspirin 75 mg orally
 - d. Give enteric-coated aspirin 325 mg rectally
- 2. A monitored patient in the ICU developed a sudden onset of narrow-complex tachycardia at a rate of 220/min. The patient's blood pressure is 128/58 mm Hg, the PETCO₂ is 38 mm Hg, and the pulse oximetry reading is 98%. There is vascular access in the left arm, and the patient has not been given any vasoactive drugs. A 12-lead ECG confirms a supraventricular tachycardia with no evidence of ischemia or infarction. The heart rate has not responded to vagal maneuvers. What is your next action?**
 - a. Administer adenosine 6 mg IV push
 - b. Administer amiodarone 300 mg IV push
 - c. Perform synchronized cardioversion at 50 J
 - d. Perform synchronized cardioversion at 200 J
- 3. A patient is in refractory ventricular fibrillation and has received multiple appropriate defibrillation shocks, epinephrine 1 mg IV twice, and an initial dose of amiodarone 300 mg IV. The patient is intubated. Which best describes the recommended second dose of amiodarone for this patient?**
 - a. 1 mg/kg IV push
 - b. 1 to 2 mg/min infusion
 - c. 150 mg IV push
 - d. 300 mg IV push
- 4. Which intervention is most appropriate for the treatment of a patient in asystole?**
 - a. Atropine
 - b. Defibrillation
 - c. Epinephrine
 - d. Transcutaneous pacing
- 5. A patient is in cardiac arrest. Ventricular fibrillation has been refractory to an initial shock. If no pathway for medication administration is in place, which method is preferred?**
 - a. Central line
 - b. Endotracheal tube
 - c. External jugular vein
 - d. IV or IO

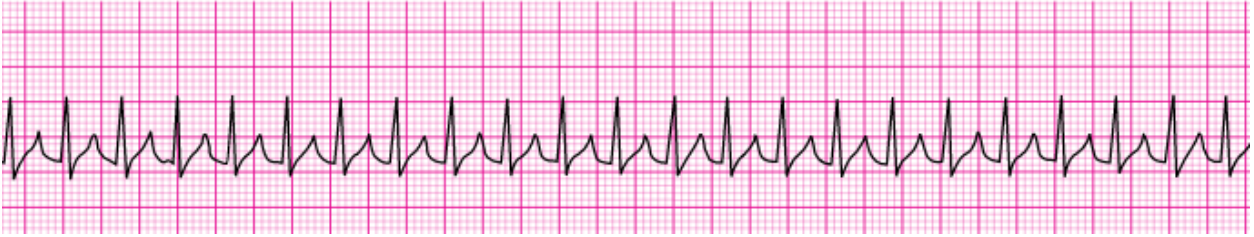
6. **A 57-year-old woman has palpitations, chest discomfort, and tachycardia. The monitor shows a regular wide-complex QRS at a rate of 180/min. She becomes diaphoretic, and her blood pressure is 80/60 mm Hg. Which action do you take next?**
- Establish IV access
 - Obtain a 12-lead ECG
 - Perform electrical cardioversion
 - Seek expert consultation
7. **You arrive on the scene with the code team. High-quality CPR is in progress. An AED has previously advised “no shock indicated.” A rhythm check now finds asystole. After resuming high-quality compressions, which action do you take next?**
- Call for a pulse check
 - Establish IV or IO access
 - Insert a laryngeal airway
 - Perform endotracheal intubation
8. **What is the indication for the use of magnesium in cardiac arrest?**
- Ventricular tachycardia associated with normal QT interval
 - Shock-refractory monomorphic ventricular tachycardia
 - Pulseless ventricular tachycardia-associated torsades de pointes
 - Shock-refractory ventricular fibrillation
9. **A patient is in refractory ventricular fibrillation. High-quality CPR is in progress. One dose of epinephrine was given after the second shock. An antiarrhythmic drug was given immediately after the third shock. You are the team leader. Which medication do you order next?**
- Epinephrine 1 mg
 - Epinephrine 3 mg
 - Sodium bicarbonate 50 mEq
 - A second dose of the antiarrhythmic drug
10. **You are caring for a 66-year-old man with a history of a large intracerebral hemorrhage 2 months ago. He is being evaluated for another acute stroke. The CT scan is negative for hemorrhage. The patient is receiving oxygen via nasal cannula at 2 L/min, and an IV has been established. His blood pressure is 180/100 mm Hg. Which drug do you anticipate giving to this patient?**
- Aspirin
 - Glucose (D50)
 - Nicardipine
 - rtPA

- 11. A patient is in pulseless ventricular tachycardia. Two shocks and 1 dose of epinephrine have been given. Which drug should be given next?**
- Adenosine 6 mg
 - Amiodarone 300 mg
 - Epinephrine 3 mg
 - Lidocaine 0.5 mg/kg
- 12. A patient is in cardiac arrest. High-quality chest compressions are being given. The patient is intubated, and an IV has been started. The rhythm is asystole. What is the first drug/dose to administer?**
- Atropine 0.5 mg IV/IO
 - Atropine 1 mg IV/IO
 - Dopamine 2 to 20 mcg/kg per minute IV/IO
 - Epinephrine 1 mg IV/IO
- 13. A 35-year-old woman has palpitations, light-headedness, and a stable tachycardia. The monitor shows a regular narrow-complex QRS at a rate of 180/min. Vagal maneuvers have not been effective in terminating the rhythm. An IV has been established. Which drug should be administered?**
- Adenosine 6 mg
 - Atropine 0.5 mg
 - Epinephrine 2 to 10 mcg/kg per minute
 - Lidocaine 1 mg/kg
- 14. A patient with possible STEMI has ongoing chest discomfort. What is a contraindication to nitrate administration?**
- Anterior wall myocardial infarction
 - Heart rate less than 90/min
 - Systolic blood pressure greater than 180 mm Hg
 - Use of phosphodiesterase inhibitor within the previous 24 hours
- 15. In which situation does bradycardia require treatment?**
- 12-lead ECG showing a normal sinus rhythm
 - Hypotension
 - Diastolic blood pressure greater than 90 mm Hg
 - Systolic blood pressure greater than 100 mm Hg
- 16. A patient has a rapid irregular wide-complex tachycardia. The ventricular rate is 138/min. He is asymptomatic, with a blood pressure of 110/70 mm Hg. He has a history of angina. What action is recommended next?**
- Giving adenosine 6 mg IV bolus
 - Giving lidocaine 1 to 1.5 mg IV bolus
 - Performing synchronized cardioversion
 - Seeking expert consultation

- 17. A patient with sinus bradycardia and a heart rate of 42/min has diaphoresis and a blood pressure of 80/60 mm Hg. What is the initial dose of atropine?**
- a. 0.1 mg
 - b. 0.5 mg
 - c. 1 mg
 - d. 3 mg
- 18. A patient is in cardiac arrest. Ventricular fibrillation has been refractory to a second shock. Which drug should be administered first?**
- a. Atropine 1 mg IV/IO
 - b. Epinephrine 1 mg IV/IO
 - c. Lidocaine 1 mg/kg IV/IO
 - d. Sodium bicarbonate 50 mEq IV/IO
- 19. A patient has a sinus bradycardia with a heart rate of 36/min. Atropine has been administered to a total dose of 3 mg. A transcutaneous pacemaker has failed to capture. The patient is confused, and her blood pressure is 88/56 mm Hg. Which therapy is now indicated?**
- a. Atropine 1 mg
 - b. Epinephrine 2 to 10 mcg/min
 - c. Adenosine 6 mg
 - d. Normal saline 250 mL to 500 mL bolus
- 20. A 62-year-old man suddenly experienced difficulty speaking and left sided weakness. He meets initial criteria for fibrinolytic therapy, and a CT scan of the brain is ordered. Which best describes the guidelines for antiplatelet and fibrinolytic therapy?**
- a. Give aspirin 160-325 mg to be chewed immediately
 - b. Give aspirin 160 mg and clopidogrel 75 mg orally
 - c. Give heparin if the CT scan is negative for hemorrhage
 - d. Hold aspirin for at least 24 hours if rtPA is administered

Section 3: Practical Application

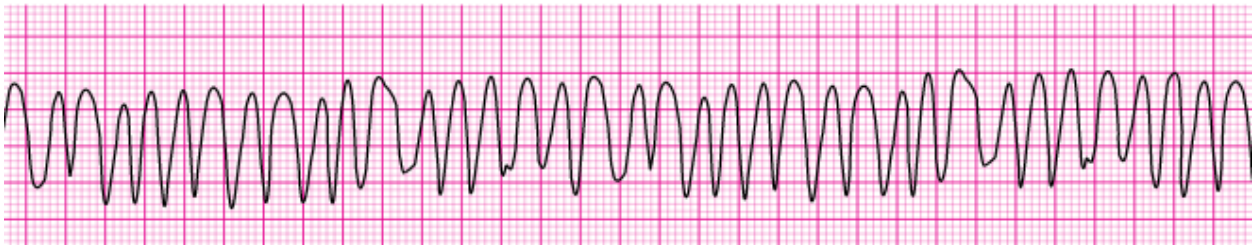
1.



A 35-year old woman presents with a chief complain of palpitations. She has no chest discomfort, shortness of breath, or light-headedness. Her blood pressure is 120/78 m Hg. Which intervention is indicated first?

- a. Adenosine 3 mg IV bolus
 - b. Adenosine 12 mg IV slow push (over 1 to 2 minutes)
 - c. Metoprolol 5 mg IV and repeat if necessary
 - d. Vagal maneuvers
2. **Your patient is not responsive and is not breathing. You can palpate a carotid pulse. Which action do you take next?**
- a. Apply an AED
 - b. Obtain a 12-lead ECG
 - c. Start an IV
 - d. Start rescue breathing
3. **What action minimizes the risk of air entering the victim's stomach during bag-mask ventilation?**
- a. Ventilating until you see the chest rise
 - b. Ventilating as quickly as you can
 - c. Squeezing the bag with both hands
 - d. Delivering the largest breath you can

4.



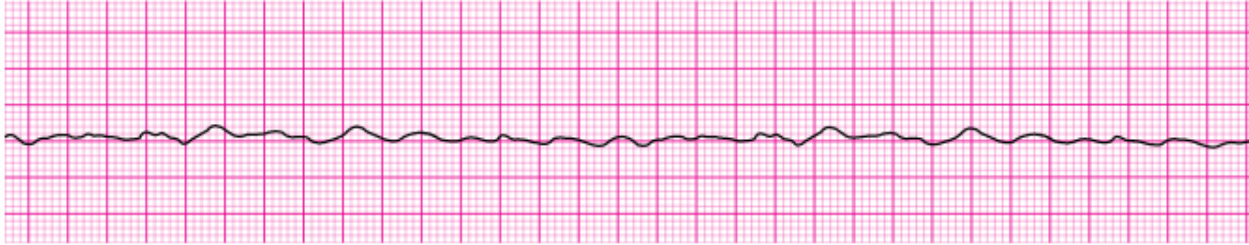
A patient has been resuscitated from cardiac arrest. During post-ROSC treatment, the patient becomes unresponsive, with the rhythm shown here. Which action is indicated next?

- a. Give an immediate unsynchronized high-energy shock (defibrillation dose)
- b. Give lidocaine 1 to 1.5 mg/kg IV
- c. Perform synchronized cardioversion
- d. Repeat amiodarone 300 mg IV

5. What is the maximum interval for pausing chest compressions?

- a. 10 seconds
- b. 15 seconds
- c. 20 seconds
- d. 25 seconds

6.



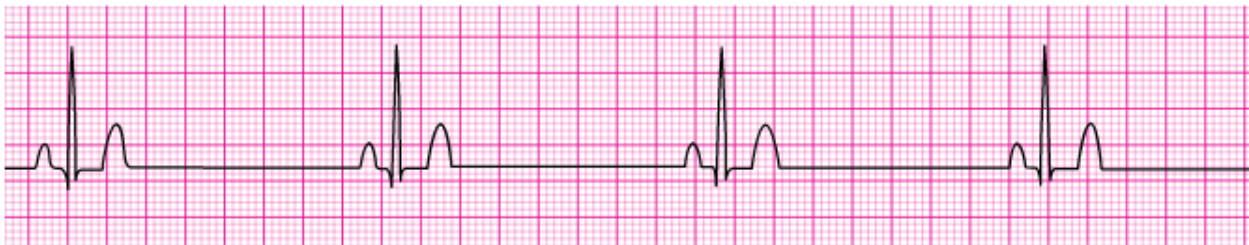After initiation of CPR and 1 shock for ventricular fibrillation, this rhythm is present on the next rhythm check. A second shock is given, and chest compressions are resumed immediately. An IV is in place, and no drugs have been given. Bag-mask ventilations are producing visible chest rise. What is your next intervention?

- a. Administer 3 sequential (stacked) shocks at 360 J (monophasic defibrillator)
- b. Give amiodarone 300 mg IV/IO
- c. Give epinephrine 1 mg IV/IO
- d. Intubate and administer 100 % oxygen

7. What is the recommended depth of chest compressions for an adult victim?

- a. At least 1.5 inches
- b. At least 2 inches
- c. At least 2.5 inches
- d. At least 3 inches

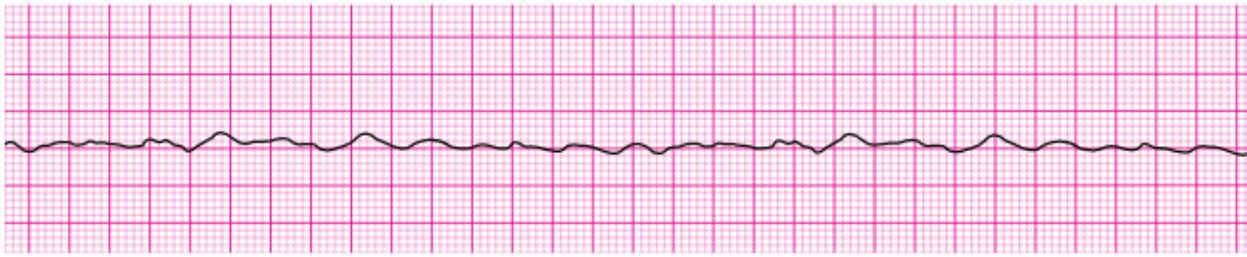
8.



Your patient is a 56-year-old woman with a history of type 2 diabetes who reports feeling dizzy. She is pale and diaphoretic. Her blood pressure is 80/60 mm Hg. The cardiac monitor documents the rhythm shown here. She is receiving oxygen at 4 L/min by nasal cannula, and an IV has been established. What do you administer next?

- a. Atropine 0.5 mg IV
- b. Dopamine at 2 to 10 mcg/kg per minute
- c. Glucose 50 % IV push
- d. Morphine sulfate 4 mg IV

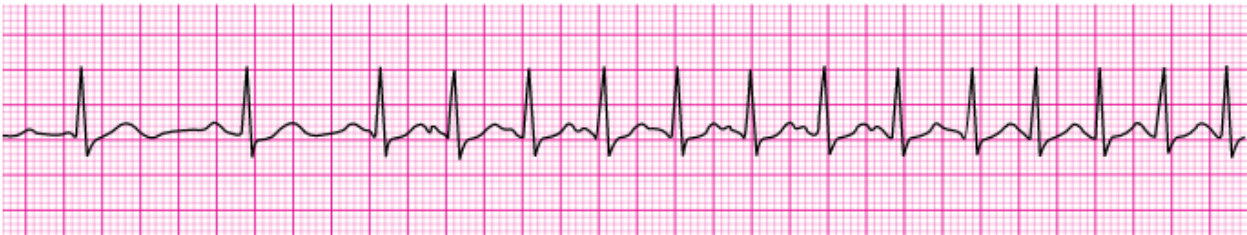9.



You arrive on the scene to find CPR in progress. Nursing staff report the patient was recovering from a pulmonary embolism and suddenly collapsed. Two shocks have been delivered, and an IV has been initiated. What do you administer now?

- a. Atropine 0.5 mg IV
- b. Epinephrine 1 mg IV
- c. Endotracheal intubation
- d. Transcutaneous pacing

10.



A 45-year-old woman with a history of palpitations develops light-headedness and palpitations. She has received adenosine 6 mg IV for the rhythm shown here, without conversion of the rhythm. She is now extremely apprehensive. Her blood pressure is 128/70 mm Hg. What is the next appropriate intervention?

- a. Administer adenosine 12 mg IV
- b. Perform unsynchronized cardioversion
- c. Perform vagal maneuvers
- d. Perform synchronized cardioversion

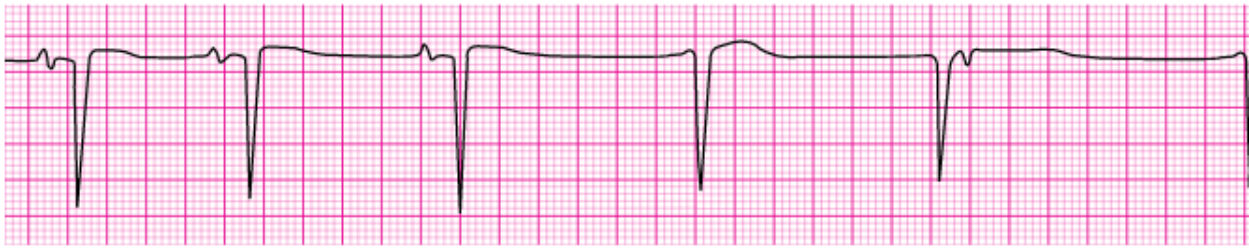
11. How does complete chest recoil contribute to effective CPR?

- a. Allows maximum blood return to the heart
- b. Reduces rescuer fatigue
- c. Reduces the risk of rib fractures
- d. Increases the rate of chest compressions

12. Which action should you take immediately after providing an AED shock?

- a. Check the pulse rate
- b. Prepare to deliver a second shock
- c. Resume chest compressions
- d. Start rescue breathing

13.



A patient becomes unresponsive. You are uncertain if a faint pulse is present. The rhythm, shown here is seen on the cardiac monitor. An IV is in place. Which action do you take next?

- a. Begin transcutaneous pacing
- b. Start high-quality CPR
- c. Administer atropine 1 mg
- d. Administer epinephrine 1 mg IV

14. How often should you switch chest compressors to avoid fatigue?

- a. About every 2 minutes
- b. About every 3 minutes
- c. About every 4 minutes
- d. About every 5 minutes

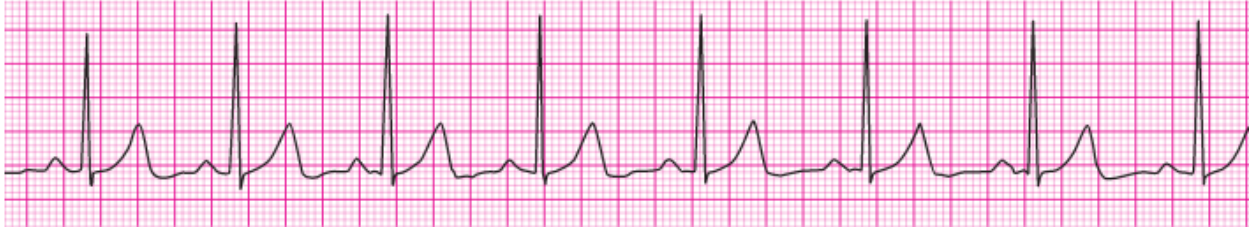15. What is the recommended compression rate for high-quality CPR?

- a. 50 to 60 compressions per minute
- b. 70 to 80 compressions per minute
- c. 90 to 100 compressions per minute
- d. 100 to 120 compressions per minute

16. You are providing bag-mask ventilations to a patient in respiratory arrest. How often should you provide ventilations?

- a. About every 5-6 seconds
- b. About every 8-10 seconds
- c. About every 12-14 second
- d. About every 17-18 seconds

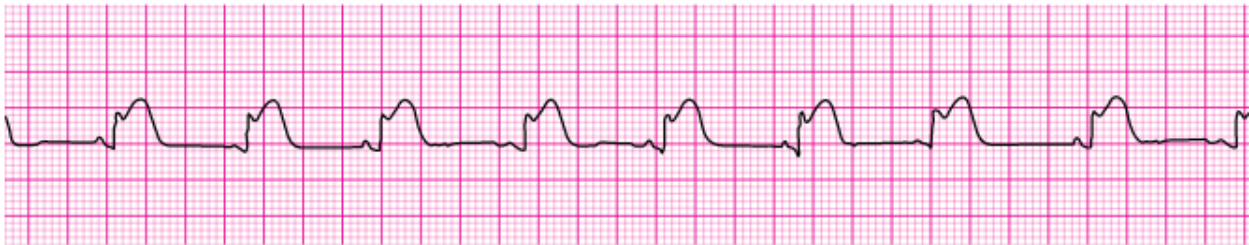17.



You are the code team leader and arrive to find a patient with CPR in progress. On the next rhythm check, you see the rhythm shown here. Team members tell you that the patient was well but reported chest discomfort and then collapsed. She has no pulse or respirations. Bag-mask ventilations are producing visible chest rise, and O₂ access has been established. Which intervention would be your next action?

- a. Atropine 1 mg
- b. Dopamine at 10 to 20 mcg/kg per minute
- c. Epinephrine 1 mg
- d. Intubation and administration of 100% oxygen

18.



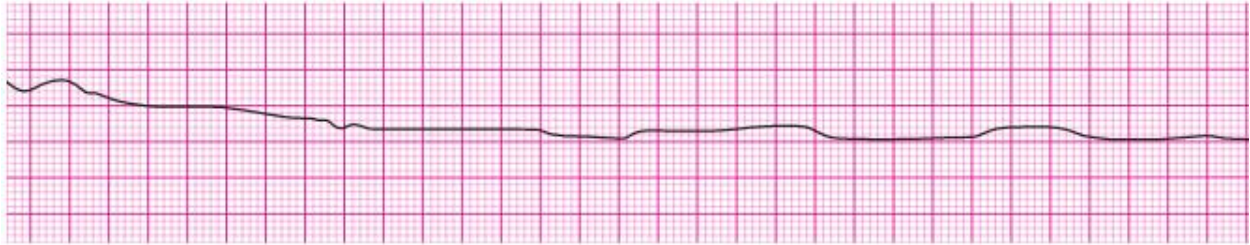
A patient's 12-lead ECG is transmitted by the paramedics and shows a STEMI. When the patient arrives in the emergency department, the rhythm shown here is seen on the cardiac monitor. The patient has resolution of moderate (5/10) chest pain after 3 doses of sublingual nitroglycerin. Blood pressure is 104/70 mm Hg. Which intervention is most important in reducing this patient's in-hospital and 30-day mortality rate?

- a. Application of transcutaneous pacemaker
- b. Atropine administration
- c. Nitroglycerin administration
- d. Reperfusion therapy

19. Which action is likely to cause air to enter the victim's stomach (gastric inflation) during bag-mask ventilation?

- a. Giving breaths over 1 second
- b. Ventilating too quickly
- c. Providing a good seal between the face and the mask
- d. Providing just enough volume for the chest to rise

20.



A patient was in refractory ventricular fibrillation. A third shock has just been administered. Your team looks to you for instructions. What is your next action?

- a. Check the carotid pulse
- b. Give amiodarone 300 mg IV
- c. Give atropine 1 mg IV
- d. Resume high-quality chest compressions

Answer Sheet

Section 1: Rhythm Identification:

1. Ventricular fibrillation
2. Third degree atrioventricular block
3. Ventricular fibrillation
4. Normal sinus rhythm
5. Second degree atrioventricular block (Mobitz 1 Wenckebach)
6. Polymorphic ventricular tachycardia
7. Sinus bradycardia
8. Agonal rhythm/asystole
9. Pulseless electrical activity
10. Sinus tachycardia
11. Second degree atrioventricular block (Mobitz 1 Wenckebach)
12. Sinus bradycardia
13. Second degree atrioventricular block (Mobitz II block)
14. Atrial flutter
15. Second degree atrioventricular block (Mobitz II block)
16. Supraventricular tachycardia
17. Monomorphic ventricular tachycardia
18. Atrial Fibrillation
19. Ventricular Fibrillation
20. Supraventricular fibrillation

Section 2: Pharmacology

1. A	2. A	3. C	4. C	5. D
6. C	7. B	8. C	9. A	10. A
11. B	12. D	13. A	14. D	15. B
16. D	17. B	18. B	19. B	20. D

Section 3: Practical Application

1. D	2. D	3. A	4. A	5. A
6. C	7. B	8. A	9. B	10. A
11. A	12. C	13. B	14. A	15. D
16. A	17. C	18. D	19. B	20. D